

## A Case of Pancreas Squamous Cell Carcinoma with Partial Response to Treatment and Poor Prognosis

Hamid Nasrollahi<sup>1</sup>, Zahra Eskandari<sup>1</sup>, Mohammad Reza Sasani<sup>2</sup>, Reza Khellat<sup>3</sup>, Seyed Hassan Hamed<sup>1</sup>, Mansour Ansari<sup>4\*</sup>, Niloofar Ahmadloo<sup>5</sup>, Shapour Omidvari<sup>6</sup>, Mohammad Mohammadianpanah<sup>7</sup>, Ahmad Mosalaei<sup>8</sup>

1 Radiation Oncologist, Radiotherapy Oncology Department, Shiraz University of Medical Sciences, Shiraz, Iran

2 Medical Imaging Research Centre, Department of Radiology, School of Medicine, University of Medical Sciences, Shiraz, Iran

3 Pathologist, Shafa Hospital, Shiraz, Iran

4 Assistant Professor in Radiation Oncology, Breast Diseases Research Center, Shiraz, Iran


5 Associate Professor in Radiation Oncology, Radiotherapy Oncology Department, Shiraz University of Medical Sciences, Shiraz, Iran

6 Professor in Radiation Oncology, Radiotherapy Oncology Department, Shiraz University of Medical Sciences, Shiraz, Iran

7 Professor in Radiation Oncology, Colorectal Research Center, Shiraz, Iran

8 Professor in Radiation Oncology, Shiraz Institute for Cancer Research, Shiraz, Iran

**\*Corresponding author: Mansour Ansari, Breast Diseases Research Center, Shiraz University of Medical Sciences, Shiraz, Iran**

 : 07136474320

 : [ansarim1999@yahoo.com](mailto:ansarim1999@yahoo.com)

## Abstract

**Introduction:** Adenocarcinoma is the most common malignancy in pancreas. Normally there is no squamous cell in pancreas. Pancreas Squamous Cell Carcinoma (SCC) is a rare tumor and its presentation is like adenocarcinoma and no specific symptom and sign is reported. Tumor markers are not helpful for this disease.

**Case presentation:** We report a 55 year-old female patient who had pancreas SCC. All investigations were normal and no other site of SCC, as a possible source for metastasis, was found. The tumor was not operable and she received 3 cycles of cisplatin and 5-fluorouracil. Then she received radiotherapy up to 44 Gy. Although she had partial response, operation was not again possible and then she received chemotherapy. Unfortunately she developed liver metastasis and passed away 9 months after diagnosis.

**Conclusion:** pancreas SCC is a rare tumor and the role of surgery and radiotherapy is not well studied. Chemotherapy is better to be administered according to SCC of other sites. Despite aggressive treatment, this malignant disease has a poor prognosis.

### Keywords:

Pancreas;  
Squamous cell  
carcinoma;Cancer

### Introduction:

Pancreas cancers are not among common human cancers and Adenocarcinoma is the most common malignancy in pancreas (1). Normal pancreas has no squamous cell, but during inflammatory processes, squamous metaplasia is seen in up to 64% of patients. It has been proposed that SCC may originate from this dysplasia.

But due to high frequency of metaplasia despite rarity of SCC, other theories are also suggested. SCC may originate from aberrant cells or may originate

from squamous changes in pre-existing adenocarcinoma. Primitive cells may also be capable of producing SCC (2, 3). Mehta et al. in 2015 mentioned that 47 cases of pancreas SCC were reported in English literature. Among these patients, autopsy or registry cases were excluded (4). We found only 3 other cases with pancreas SCC in PubMed and Google Scholar (5, 6, 7). So, as we know only 50 cases of pancreas SCC are reported in English literature. Few are known about clinical course, treatment and outcome. Herein, we want to share our

experience about a case of pancreas SCC and her poor outcome.

### Case presentation:

Patient was a healthy and well 55 year-old woman with 3 children till having an abdominal pain for 2 months before being visited in November 2016. Past medical history was not significant and she had no jaundice or pruritis or other symptoms of billiary obstruction. There was no history of smoking or gall stone, alcohol consumption and also family history was not significant. Complete blood count, renal and hepatic function tests and urine analysis were normal. In abdominal sonography a pancreatic mass found and the abdominal, pelvis and chest CT scan was done showing a lesion in the head of pancreas and no other lesion (fig 1).

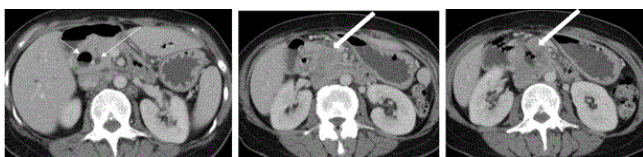

Figure 1: abdominal CT images showing a cavitory mass lesion (thick arrows) involving inferior part of pancreatic head with obliteration and proximal dilatation of the pancreatic duct (long thin arrow) and common billiary duct (short thin arrow).

Trucut biopsy from the mass was taken that showed SCC (fig 2).

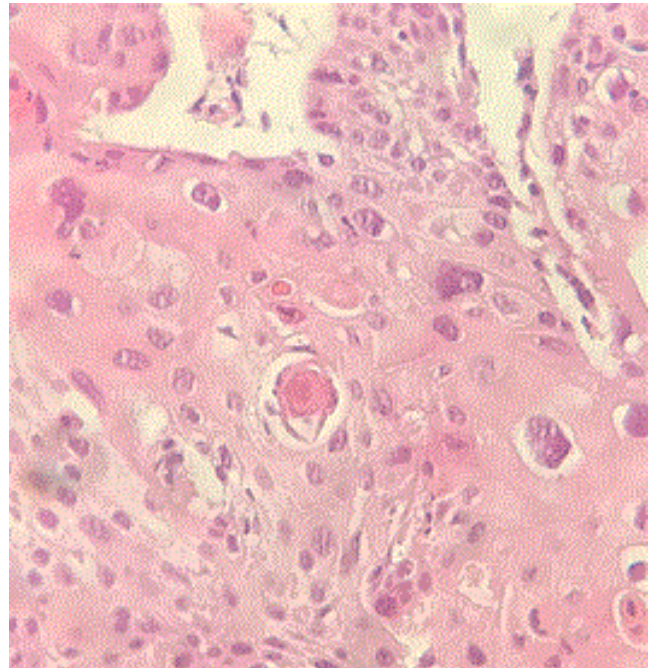


Figure 2: Histologic section show fragments of malignant keratinizing squamous epithelial cells with high N/C ratio, nuclear hyperchromatism and irregular nuclear border admixed with focus of gastric type mucosa

Head and neck and esophageal evaluations were done to find possible primary site that were normal. She received 3 cycles of cisplatin (100mg/m<sup>2</sup> day 1) and 5-fluorouracil (1000 mg/m<sup>2</sup> for 3 days) and then irradiation to tumor and regional lymph nodes up to 44 Gy in May 2017. Her tumor partially responded to treatment but was not operable yet. Patient became weak after chemotherapy and radiotherapy and consequently received chemotherapy with single agent Docetaxel (75mg/m<sup>2</sup>). After 2 months, she developed liver metastasis and passed away in September 2017.

## Discussion:

Clinical manifestation of pancreas SCC is like other primary cancers of pancreas, including jaundice, abdominal pain, anorexia and nausea and vomiting (3). The most common presentations were abdominal pain and weight loss (4). Our patient had abdominal pain. Physical examination may be normal. Otherwise jaundice, abdominal tenderness or abdominal mass may be found (4). Minami reported a case of pancreas SCC that presented with melena. The tumor had invaded to stomach and caused bleeding (8). In Mehta's review, mean age was 63 (33-80) years and both genders were involved equally. Our patient was a 55 year-old woman (4, 9).

When SCC is found in pancreas, other possible primary tumors must be ruled out at first (1). Pancreas SCC is avid to [18F]-2-fluoro-2-deoxy-D-glucose (FDG). PET-CT scan is a helpful tool to detect primary origin of tumor in metastatic cases and finding metastasis in cases of primary pancreas SCC (10). Our patient was not able to do PET-CT scan and it is the main drawback of our report. But neck, chest and abdominopelvic CT scans were normal. Esophago-gastric endoscopy and ENT examination were also normal. We treated her as a primary pancreas SCC.

As in our case, most common site for pancreas SCC is the head of pancreas (3). But there are

other reports that pancreas SCC was found in tail or body (4, 11).

In contrast to adenocarcinoma, no serum marker is available for pancreas SCC. In most reports that we found, tumor markers were in normal limit or occasionally slightly increased (3, 6, 12-14). But in 3 reports, CA 19-9 was 23, 23 and 12 times higher than normal. Two of these cases had a dismal clinical course and in 1 report, clinical course was not mentioned (2-4). Hypercalcemia in the absence of bone metastasis or humoral hypercalcemia of malignancy is also reported in pancreas SCC (3). Minami also reported that serum squamous cell carcinoma-related antigen (SCC-Ag) may be a reliable factor for disease activity (8). Kashani et al reported a case of pancreas SCC with elevated CEA and CA-125 in addition to CA19-9. In this 76 year-old female patient, CEA, CA 19-9 and CA-125 were 75, 22 and 48 times of upper limit of normal. This patient developed liver metastasis soon after surgery (2).

Treatment of pancreas SCC is not well defined. These tumors are treated as primary SCCs of other sites or as adenocarcinoma of pancreas (4). Primary SCCs in other sites are usually responsive to chemotherapy and radiotherapy, but it seems that in pancreas, SCC does not so well (10). Combination chemotherapy with Gemcitabine-cisplatin was successful in controlling tumor growth in a 61 year-old man; however, tumor had regrowth after

4 months (15). Kodavatiganti reported successful tumor control with Combination chemotherapy with cisplatin and 5-fluorouracil in a case of pancreas SCC with liver metastasis. Chemotherapy produced partial response and he was well for 6 months. Then he developed local recurrence and was unable to tolerate 2nd line chemotherapy and passed away (10). Unfortunately this regimen was not successful in another report (1). Our patient received cisplatin-fluorouracil for 3 cycles and then radiotherapy alone. Although tumor responded to treatment, it did not become operable.

Brijbassie reported a case of pancreas SCC that had tumor progression after Chemo-radiotherapy. Chemotherapy agents and dose was not mentioned (3). Nikfam reported a 66 year-old woman with pancreas SCC who received gemcitabine. Chemotherapy was not successful and she developed metastasis to liver and trachea. The size of pancreas lesion also increased and she passed away (11).

Median survival is reported to be about 7 months (3). In inoperable cases, mean survival decreases to 3 months (3). It seems that those patients, who cannot be operated, have a dismal outcome (1). Adachi et al. reported a 67 year-old woman with a pancreas SCC who developed recurrence after complete tumor resection (12). She developed recurrence and radiotherapy was not successful in tumor control (12). Carboplatin-gemcitabine

combination chemotherapy was not successful in pancreas SCC (9).

Schultheis reported a 57 year-old woman with pancreas SCC that showed a good response to neoadjuvant treatment. She received irradiation (54 Gy) in combination with gemcitabine (300 mg/m<sup>2</sup>). Her tumor volume decreased and was completely removed and at the time of report, she was well for 7 months (16). Kridis reported a case of pancreas SCC who was disease free for 26 months. He had received chemotherapy including 5-fluorouracil and folinic acid (1).

### **Conclusion:**

Pancreas SCC is a rare tumor and the role of surgery and radiotherapy is not well studied. Chemotherapy is better to be administered according to SCC of other sites. Despite aggressive treatment, this malignant disease has a poor prognosis.

### **Authors' Contributions:**

All the authors have equally contributed to the manuscript and approved the final version.

### **Conflict of Interest Disclosures:**

There are no conflicts of interest in terms of the present manuscript.

### **Ethical approval/Consideration:**

A written informed consent was signed by patient

for reporting her case. All the personal information remained a nonymous.

### Reference:

1. Ben Kridis W, Khanfir A, Toumi N, Ben Amar M, Boudawara T, Frikha M. Primary squamous cell carcinoma of the pancreas: a report of two cases and review of the literature. *Internal medicine*. 2015;54(11):1357-9.
2. Kashani A, Kahn M, Jamil LH. Diagnosis of primary squamous cell carcinoma of the pancreas using endoscopic ultrasound-guided core needle biopsy. *Gastroenterology report*. 2015.
3. Brijbassie A, Stelow E, Shami VM. Squamous Cell Carcinoma of the Pancreas: A Case Report and R eview of Literatur we. *Gastroenterology research*. 2014;7(3-4):102-4.
4. Mehta M, Sinha J, Ogawa M, Ganguly A, Xiang D, Poddar N. Unusual Case of Squamous Cell Carcinoma of Pancreas with Review of Literature. *Journal of gastrointestinal cancer*. 2015;46(4):426-9.
5. Rowe K, Mehta J, Nehme F, Salyers W. Primary Squamous Cell Carcinoma of the Pancreas as a Cause of Biliary Obstruction. *Cureus*. 2016;8(10):e856.
6. Modi RM, Kamboj AK, Shen R, Krishna SG. Endosonography and Confocal Endomicroscopy of Primary Keratinizing Squamous Cell Carcinoma of the Pancreas. *ACG case reports journal*. 2017;4:e17.
7. Raghavapuram S, Vaid A, Rego RF. Squamous Cell Carcinoma of Pancreas: Mystery and Facts. *The Journal of the Arkansas Medical Society*. 2015;112(3):42-3.
8. Minami T, Fukui K, Morita Y, Kondo S, Ohmori Y, Kanayama S, et al. A case of squamous cell carcinoma of the pancreas with an initial symptom of tarry stool. *Journal of gastroenterology and hepatology*. 2001;16(9):1077-9.
9. Al-Shehri A, Silverman S, King KM. Squamous cell carcinoma of the pancreas. *Current oncology*. 2008;15(6):293-7.
10. Kodavatiganti R, Campbell F, Hashmi A, Gollins SW. Primary squamous cell carcinoma of the pancreas: a case report and review of the literature. *Journal of medical case reports*. 2012;6:295.
12. Adachi K. Primary squamous cell carcinoma of the pancreas: a case report. *JOP : Journal of the pancreas*. 2011;12(2):181-4.
11. Nikfam S, Sotoudehmanesh R, Pourshams A, Sadeghipour A, Sotoudeh M, Mohamadnejad M. Squamous cell carcinoma of the pancreas. *Archives of Iranian medicine*. 2013;16(6):369-70.

13. Terada T. Adenosquamous Carcinoma and Pure Squamous Cell Carcinoma of the Pancreas: Report of two Cases. *Case reports in gastroenterology*. 2010;4(3):369-73.
14. Brégeaud L, Ruszniewski P, Bernades P, Belghiti J, Fléjou J-F. Squamous cell carcinoma and lipomatous pseudohypertrophy of the pancreas. *Virchows Archiv : an international journal of pathology*. 1999;434:569-72.
15. De Souza AL, Saif MW. Squamous cell carcinoma of the pancreas. *JOP : Journal of the pancreas*. 2014;15(6):630-1.
16. Schultheis AM, Nguyen GP, Ortmann M, Kruis W, Buttner R, Schildhaus HU, et al. Squamous Cell Carcinoma of the Pancreas in a Patient with Germline BRCA2 Mutation-Response to Neoadjuvant Radiochemotherapy. *Case reports in oncological medicine*. 2014;2014:860532.